

Photo Quiz: Bone Lesion to the Neck of the Talus

Vasu Pai MS, D[Orth], National board [Orth], FICMR, FRACS, MCh[Orth]¹ ✉, Vishal Pai, M.B., Chb²

The Foot & Ankle Journal 1 (6): 5

ISSN 1941-6806 doi: 10.3827/faoj.2008.0106.0005

Case History

An 8 year old boy presents with history of ankle pain for 4 months. His pain is mainly to the anterior aspect of the ankle joint. He had been limping for last 6 weeks. Clinical evaluation reveals tenderness over the dorsal aspect of the talus. The dorsiflexion of the ankle was terminally limited and extremely painful. The subtalar joint was normal. There is normal heel inversion on standing tip-toe.

Laboratory data was unremarkable. As symptoms did not settle at 6 months, the joint was aspirated under anesthesia. Two milliliter of straw colored fluid was aspirated from the ankle joint. Gram stain was negative and culture did not reveal any growth of organisms. Cell count was less than 2000 and suggestive of non-specific synovitis.

The plain radiograph of the ankle and foot is normal. The bone scan revealed an increased uptake in the left side of the talus. The CT scan revealed a small lesion which could be identified over the superior border of the talus with surrounding sclerosis. The MRI revealed increase signal intensity in T2 and decrease signal intensity in T1. (Fig. 1) There was increased enhancement with post gadolinium injection. A benign lesion was diagnosed.

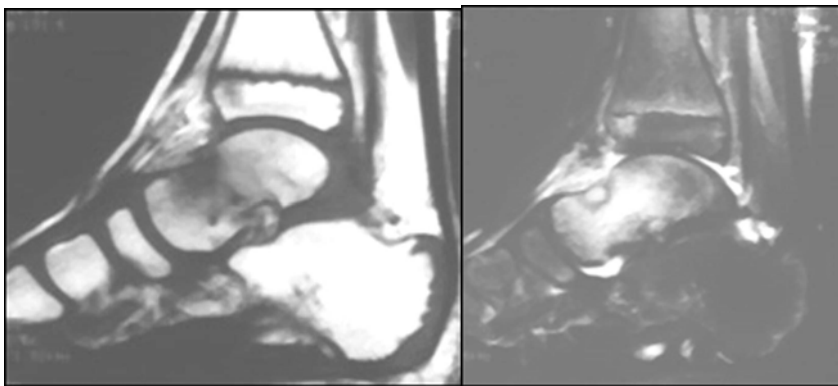


Figure 1 T1 and T2 MRI shows signal intensity changes involving the neck of the talus.

The left ankle was surgically explored through an antero-lateral approach. The sensory branch of musculocutaneous nerve was preserved. The neck of the talus superiorly was irregular and was curetted very easily. (Fig. 2) The wound was closed in layers. The ankle was held in a neutral position in a short leg cast.

Histopathological examination showed abundant osteoid in fibrovascular stroma. The trabeculae were rimmed by prominent osteoblasts with no mitotic activity. (Fig. 3) At one year follow up there was no recurrence or the lesion. Patient is now totally asymptomatic.

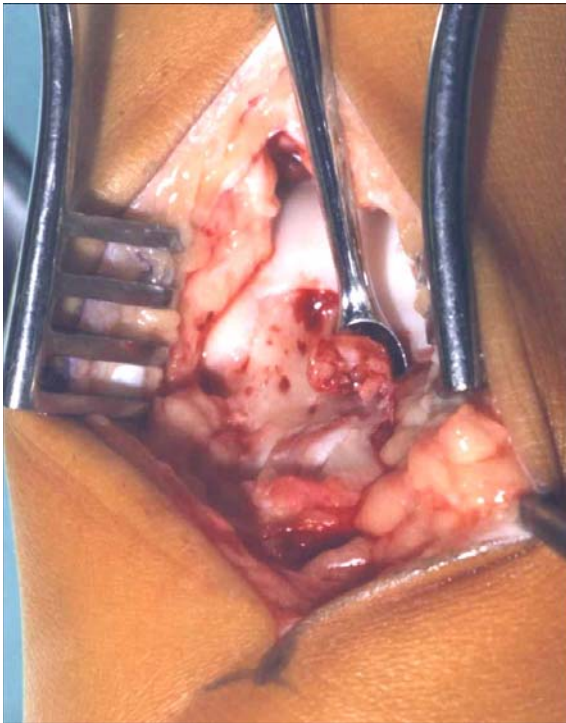


Figure 2 Irregular, soft, cystic-like material is easily curetted from the neck of the talus.

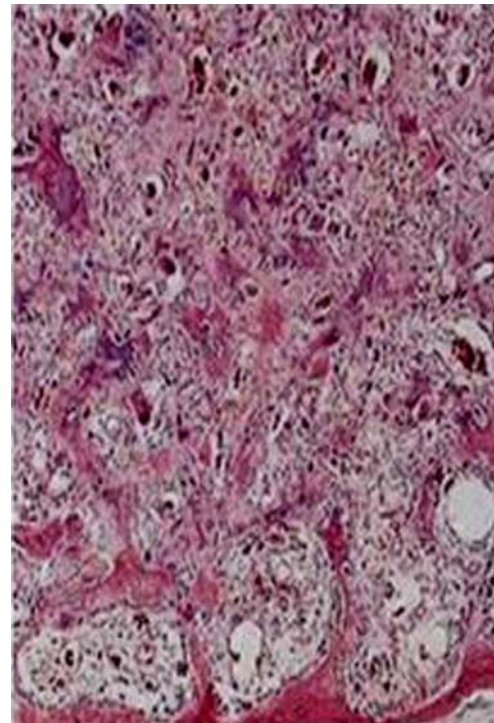


Figure 3 Trabeculae rimmed by prominent osteoblasts in fibrovascular stroma.

Question: Based on the patient's clinical history, MRI ,surgical and histologic findings, which of the following is the correct diagnosis?

- A. Osteochondritis dessicans (OCD lesion)
- B. Atypical Osteoid Osteoma
- C. Osteblastoma
- D. Brodie's Abscess
- E. Ewing's tumor

Address correspondence to: Dr. Vasu Pai, Gisborne Hospital, Ormand Road, Gizborne, New Zealand.
E-mail: vasuchitra@gmail.com

¹Orthopaedic Specialist, Gisborne, Hospital, Ormand Road, Gisborne, New Zealand.

²House Surgeon, Middlemore Hospital, Auckland, New Zealand.